

# Palatal bone support for orthodontic implant anchorage—a clinical and radiological study

Heinrich Wehrbein, Beat R. Merz\* and Peter Diedrich\*\*

Clinic for Orthodontics, Free University of Brussels, Belgium, \*Institut Straumann AG, Waldenburg, Switzerland and \*\*Klinik für Kieferorthopädie, Medizinische Fakultät, RWTH Aachen, Germany

**SUMMARY** When maximal anchorage is required during orthodontic treatment, additional aids are often needed to support the anchoring teeth. While intra-oral aids may be limited in their anchorage potential, extra-oral anchoring aids are often rejected by the patients. Endosseous implants may therefore be a valuable alternative for stable intra-oral anchorage. However, the possibility of using conventional implants is insufficient, e.g. for treating purely orthodontic patients with full dentition or where extraction sites are to be closed. Therefore, the mid-sagittal area of the palate is an alternative insertion site for the placement of implants for orthodontic anchorage.

The limited bone height in this area inspired this comparison between bone thickness in the implantation site as verified by probing during the implantation of Straumann Orthosystem implants, and thickness as measured on the lateral cephalogram.

The results suggest that vertical bone support is at least 2 mm higher than apparent on the cephalogram. In none of 12 patients was a perforation to the nasal cavity found. However, in five subjects the implant projected into the nasal cavity on the post-operative cephalogram. These results were supported by the study of the projections of palate and wires in wire-marked skulls where the wires were placed bilaterally on the nasal floor and on the nasal crest.

It is therefore concluded that the mid-sagittal area of the palate lends sufficient bony support for the implantation of small implants (4–6 mm endosseous length, diameter 3.3 mm).

## Introduction

When stationary anchorage is required in the course of orthodontic treatment, additional aids are often needed to support anchoring teeth. Because of limited anchorage potential and acceptance problems of conventional intra- or extra-oral anchorage aids, implants as a means for orthodontic anchorage are gaining increased importance in orthodontic treatment.

To date, mainly prosthetic implants in the alveolar bone have been used for orthodontic correction as the first step in overall treatment (e.g. Kokich, 1994; Ödman *et al.*, 1994; Schweizer *et al.*, 1996). However, the possibility of using conventional implants in alveolar bone is not sufficient for covering the spread of applications in the clinical practice of orthodontics. Purely

orthodontic patients require other treatment schemes since they have a full dentition or require extraction sites to be closed. In these cases the alveolar bone is not available and therefore implants need to be placed temporarily into other anatomical regions.

Roberts *et al.* (1989), and Higuchi and Slack (1991) described the use of temporary implants in the retromolar area for maximal anchorage in the mandible. Triaca *et al.* (1992), Block and Hoffman (1995) and Wehrbein *et al.* (1996a,b) have described the mid-sagittal area of the palate as an insertion site for implant anchorage in orthodontic treatment of the maxilla.

In the palate different concepts have been followed. Block and Hoffman (1995) introduced a subperiosteal disc of 10 mm diameter. Triaca *et al.* (1992) used a screw-type implant with a low

height of 3 mm and a wide diameter of 7.5 mm, while Wehrbein *et al.* (1996a,b) introduced an implant with a small diameter (3.3 mm) and a low-to-medium length (4 and 6 mm). The subperiosteal and the low-height concept are more invasive from the soft tissue point of view, but bone height is less of a problem. The low to medium length concept is less invasive with respect to the soft tissue, but requires sufficient bone support. Hence, the bone-height available is an important factor for the placement of such implants.

Therefore, although the latter endosseous orthodontic implants are small in dimension, the vertical bone height in the insertion site has to be evaluated carefully to avoid the risk of perforations to the nasal cavity. As a lateral cephalogram is already available for orthodontic treatment planning, the same radiograph should be used for assessment of the vertical bone height in the area of the palatal suture.

It was the aim of the present study to evaluate bone height in the mid-sagittal region and to compare the cephalometric assessment with the clinical results obtained during insertion of orthodontic implants. Additionally, three wire-marked skulls were radiographed to evaluate the projection of the relevant anatomical structures on the cephalograms.

## Subjects and methods

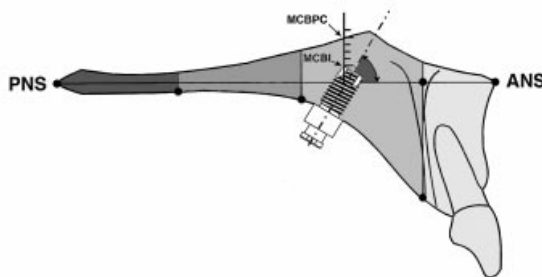
Twelve patients (six male, six female) aged 15–39 years received a Straumann Orthosystem implant (Institut Straumann AG, Waldenburg, Switzerland) in the mid-sagittal palatal area for achieving maximum anchorage in the maxilla during orthodontic treatment.

The methodological procedure was as follows: on the lateral cephalogram the fitting implant size was determined by assessing the apparent vertical bone height in the desired implantation site. At surgery the palatal mucosa was removed by a standard punch, followed by the drilling of the endosseous cavity using a pilot drill and a profile drill. Careful probing was then performed by means of a sterilized periodontal probe (Brod 25 G, Ash, Weybridge, UK) set to indicate a force of 0.2 N in order to detect any

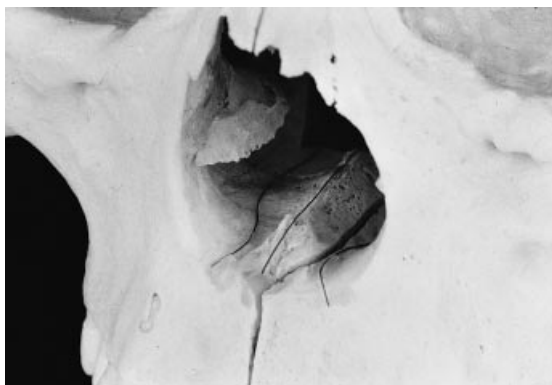bony perforation to the nasal sinus. When careful probing at different locations at the apical end of the drilled implant cavity revealed a resistance of 0.2 N, the finding was classified as no perforation to the nasal cavity. During this probing, the bony quality of the cavity bottom was also assessed by careful scratching (crepitatio) with the probe. Subsequently, the implant was inserted. In the same session a standardized lateral cephalogram was taken with the Ortophos C scanner (Siemens, Bensheim, Germany; 77–80 kV, 14 mA, 0.64–0.8 seconds) to compare the radiological findings with the results of the probing.

The parameters for radiological assessment were: the position of the implant with respect to the section of the palate, the angulation of the implant to the palatal plane (Figure 1) and the distance between the most cranial border of the implant (MCBI) and the radiologically verifiable most cranial border of the palatal complex (MCBPC). To analyse the latter criteria the borders of the relevant structures and the scale on the cephalograms were drawn on foil using a sharp pencil. The schematic drawing in Figure 1 clarifies the details: a line perpendicular to the palatal plane was constructed passing through the point representing the MCBPC. The distance between the MCBI and the MCBPC was then measured on this line to the nearest 0.1 mm with a calibrated slide gauge.

In order to study the details of the projection of the palatal region on the lateral cephalograms



**Figure 1** Definition of position and angulation of the implant in the mid-sagittal palate. The palate is divided into three sections. The distance between the radiologically verifiable most cranial border of the palatal complex MCBPC and the most cranial border of the implant MCBI is measured, as well as the angle between implant axis and the ANS/PNS line.



**Figure 2** Wire-marked skull: two wires were placed, one on either side of the nasal spine onto the nasal floor, and a third wire onto the nasal crest.

three skulls were radiographed. Subsequently, they were marked with wires and radiographed again. Two wires were placed on the nasal floor, one on either side of the nasal spine, and a third wire was placed on top of the nasal crest (Figure 2). The radiographs with and without wires were then compared in order to observe the differences between the apparent borders of bone structures on the radiograph and the effective borders as indicated by the wires.

## Results

Table 1 gives an overview of the 12 patients and the results measured, and Table 2 shows the results with respect to position, angulation, and implant length (cf. Figure 1). Eight of the 12 implants were inserted into the anterior section of the mid-sagittal palate with a mean angulation of 62 degrees (SD = 12 degrees, range = 41–71 degrees). All of these implants were of 6 mm length. Four implants were positioned in the mid-section of the palate with a mean angulation of 70 degrees (SD = 5 degrees, range = 62–78 degrees). Of these implants three were 4 mm and one was 6 mm in length. Consideration of these angles is of special significance as the smaller the angulation of the implant, the more favourable the vertical bone support at a given implant length.

Table 3 reports the results of the radiological measurement in association with probing of the endosseous cavity. According to the vertical relationship between the MCBI and the MCBPC the patients were divided into two groups. Group I comprised seven patients in whom the MCBI projected below the MCBPC. Figure 3 gives an example of the lateral cephalogram in such a case. The mean distance MCBI-MCBPC was +1.6 mm. As expected, probing revealed no

**Table 1** Overview of the patients and corresponding parameters.

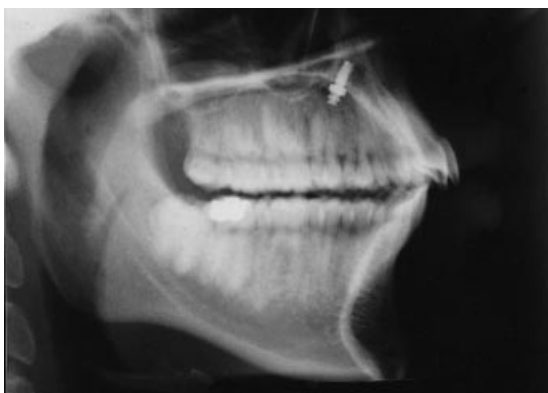Patient no.	Age	Sex	Implant length/neck length (mm)	Section of the palate		Angulation to ANS/PNS (degrees)	Distance (mm)	
				anterior	median		MCBPC (mm) MCBI below	MCBPC (mm) MCBI above
1	32	m	6/2.5	x		71		2.0
2	39	m	4/2.5		x	68	0.2	
3	36	f	4/2.5		x	62		1.7
4	31	m	6/2.5	x		41	4.5	
5	32	f	6/2.5	x		61		2.1
6	24	m	6/1.5	x		57	4.5	
7	34	f	6/1.5		x	72		2.1
8	22	f	6/1.5	x		71	0.0	
9	15	f	6/1.5	x		65		1.9
10	27	f	4/1.5		x	78	0.3	
11	21	m	6/2.5	x		66	0.6	
12	23	m	6/2.5	x		64	1.2	

**Table 2** Position, angulation, and length of the different implants.

		Section of palate	
		anterior	middle
Number of implants		8	4
Angulation ANS/PNS	Mean (SD)	62° ( $\pm 12^\circ$ )	70° ( $\pm 5^\circ$ )
	min./max.	41/71°	62/78°
Implant length/number	4 mm	—	3
	6 mm	8	1

**Table 3** Comparison between radiological measurements and probing.

Group		I ( <i>n</i> = 7)	II ( <i>n</i> = 5)
MCBI/MCBPC		MCBI below MCBPC	MCBI above MCBPC
Distance MCBI/MCBPC (mm)	mean (SD)	+ 1.6 ( $\pm 2.1$ )	-1.9 ( $\pm 0.2$ )
	min./max.	0.0/4.5	1.7/2.1
Perforation on probing	yes	—	—
	no	7	5
Implants, section of palate	anterior	5	3
	middle	2	2



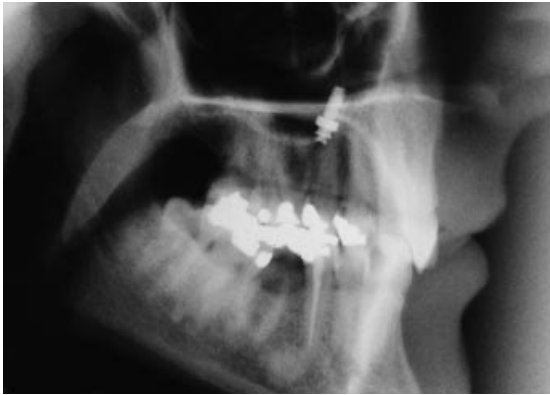**Figure 3** The post-operative cephalogram of a patient with a dental Class II division 1 malocclusion and anterior crowding. The treatment goal was extraction of the first premolars and retraction and alignment of the anterior teeth with bilateral maximal posterior anchorage. No projection of the implant into the nasal sinus and no perforation on probing were found.

perforation to the nasal cavity in any patient of this group.

Group II comprised the remaining five cases in which the MCBI projected above the MCBPC. Therefore, in this group the top of the implant projected into the nasal cavity as exemplified in Figure 4. The mean distance MCBI-MCBPC measured was -1.9 mm. However, probing of the endosseous implant cavity revealed no perforation to the nasal cavity in any of these patients. Three implants were positioned in the anterior and two in the mid-section of the mid-sagittal palate.

These results suggest that vertical bone support in the anterior and mid-section of the palate is somewhat higher than indicated on the cephalograms.

This is confirmed by first results of a study with wire-marked skulls (Figure 2) where the

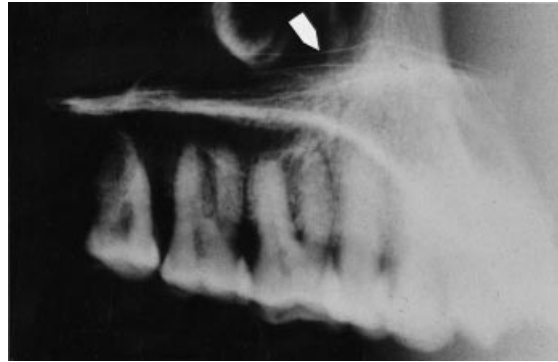

**Figure 4** Post-operative cephalogram of a patient with a skeletal Class I and a dental Class II division 1 malocclusion. The treatment goals were distalization of the lateral teeth and torquing of the incisors. The implant projects into the nasal sinus, however, there was no perforation to the nasal sinus found during intra-operative probing.

position of the wires indicating nasal floor and nasal spine on the cephalogram were compared to the projection of borders of the hard palate (Figure 5). The radiologically visible MCBPC corresponds largely with the anatomical structure of the basal nasal cavity and not with the mid-sagittally situated nasal crest which offers additional vertical bone support.

## Discussion

The mid-sagittal area of the palate is a valuable insertion site for implants in order to provide a stable point for orthodontic correction in the maxilla in subjects with a full dentition or where spaces are to be closed. With respect to the given limitations in bone height a study was carried out, based on clinical and radiological data obtained during and after insertion of implants, which were placed in the anterior and middle sections of the mid-sagittal palate. The results suggest that sufficient vertical bone support is available in this area for implants of 4 and 6 mm endosseous length, and with a diameter of 3.3 mm. The results also show that vertical bone support is mid-sagittally at least 2 mm higher than indicated on the cephalograms. The angulation of the implant has a considerable influence



**Figure 5** Lateral cephalogram of the wire-marked skull (cf. Figure 2). The wire on the crest (arrow) seems to be suspended in the air since the crest is not visible on the projection.

on the remaining vertical bone height above the MCBI. The smaller the angle between ANS-PNS and the implant axis, the more residual bone is available above the MCBI. The angulation, however, cannot be selected freely because it depends on the position in the palate and the angulation of the lingual surface of the palate. In general the implant should be inserted approximately orthogonal to the buccal surface of the palate such that a seat can easily be created by the profile drill at insertion time and the mucosa reaches about the same height around the transmucosal cylinder. It is also of importance to select a position which does not affect the incisal foramen.

The present results are of some impact for treatment planning before implant insertion with respect to evaluation of the available bone quantity and to the selection of an adequate implant length, position, and angulation. When carefully considering these issues in planning, the potential risk of a perforation to the nasal cavity may be minimized or even avoided. If, however, a slight perforation of the bony structures should occur, the thick nasal mucosa will prevent an open connection to the nasal sinus.

Nevertheless, by good planning and careful evaluation of the cephalograms, even a bony perforation should and can be omitted when implanting in the mid-palatal area using the additional height provided by the nasal crest.

Based on the results of this study the following recommendations can be made: potential implant length, position, and angulation should be selected such that the level of the MCBI projects maximally onto the level of the radiologically detectable MCBPC in this area. Thus, a safety distance to the nasal sinus of at least 2 mm should be present. In fact, these considerations may be of special importance to patients with primary low vertical bone height when orthodontic implant anchorage is required.

#### Address for correspondence

Dr B. Merz  
Institut Straumann AG  
CH-4437 Waldenburg  
Switzerland

#### References

- Block M S, Hoffman D R 1995 A new device for absolute anchorage for orthodontics. *American Journal of Orthodontics and Dentofacial Orthopedics* 107: 251–258
- Higuchi K W, Slack J M 1991 The use of titanium fixtures for intra-oral anchorage to facilitate orthodontic tooth movement. *International Journal of Oral & Maxillofacial Implants* 6: 338–344
- Kokich V G 1994 Die Verwendung von Implantaten zur Kieferorthopädischen Zahnbewegung. Informationen aus der orthodontischen Kieferorthopädie 1: 31–43
- Ödman J, Lekholm U, Jemt T, Thilander B 1994 Osseo-integrated implants as orthodontic anchorage in the treatment of partially edentulous patients. *European Journal of Orthodontics* 16: 187–201
- Roberts W E, Helm F R, Marshal K J, Gongloff R K 1989 Rigid endosseous implants for orthodontic and orthopedic anchorage. *Angle Orthodontist* 59: 247–256
- Schweizer C M, Schlegel K A, Rudzki-Janson I 1996 Endosseous dental implants in orthodontic therapy. *International Dental Journal* 46: 61–68
- Triaca A, Antonini M, Wintermantel E 1992 Ein neues Titan-Flachschrauben-Implantat zur orthodontischen Verankerung am anterioren Gaumen. Informationen aus der orthodontischen Kieferorthopädie 24: 251–257
- Wehrbein H, Glatzmaier J, Mundwiler U, Diedrich P 1996a The Orthosystem—a new implant system for orthodontic anchorage in the palate. *Journal of Orofacial Orthopedics* 57: 142–153
- Wehrbein H, Merz B R, Diedrich P, Glatzmaier J 1996b The use of palatal implants for orthodontic anchorage. Design and clinical application of the Orthosystem. *Clinical Oral Implant Research* 7: 410–416